

■ SPINE

Decision-making in lumbar spinal stenosis

A SURVEY ON THE INFLUENCE OF THE MORPHOLOGY OF THE DURAL SAC

C. Schizas,
G. Kulik

From Centre
Hospitalier
Universitaire
Vaudois, University
of Lausanne,
Lausanne,
Switzerland

Surgical decision-making in lumbar spinal stenosis involves assessment of clinical parameters and the severity of the radiological stenosis. We suspected that surgeons based surgical decisions more on dural sac cross-sectional area (DSCA) than on the morphology of the dural sac. We carried out a survey among members of three European spine societies. The axial T2-weighted MR images from ten patients with varying degrees of DSCA and morphological grades according to the recently described morphological classification of lumbar spinal stenosis, with DSCA values disclosed in half the assessed images, were used for evaluation. We provided a clinical scenario to accompany the images, which were shown to 142 responding physicians, mainly orthopaedic surgeons but also some neurosurgeons and others directly involved in treating patients with spinal disorders. As the primary outcome we used the number of respondents who would proceed to surgery for a given DSCA or morphological grade. Substantial agreement among the respondents was observed, with severe or extreme stenosis as defined by the morphological grade leading to surgery. This decision was not dependent on the number of years in practice, medical density or specialty. Disclosing the DSCA did not alter operative decision-making. In all, 40 respondents (29%) had prior knowledge of the morphological grading system, but their responses showed no difference from those who had not. This study suggests that the participants were less influenced by DSCA than by the morphological appearance of the dural sac.

Classifying lumbar spinal stenosis according to morphology rather than surface measurements appears to be consistent with current clinical practice.

Patients with lumbar spinal stenosis resistant to conservative measures are generally considered suitable for surgical decompression,¹ but as with many surgical conditions the indications are not clearly defined. Although several prospective randomised trials have compared surgical with non-surgical management of spinal stenosis, some authors have not proposed a radiological threshold for operative intervention,^{2,3} whereas others used the cross-sectional area of the dural sac (DSCA) but gave no explanation of its relationship to results.⁴

Evidence-based guidelines for the treatment of lumbar spinal stenosis have been published but did not include radiological thresholds.¹ The most commonly used radiological measure of lumbar spinal stenosis is the DSCA measured in axial MR scans at disc level.⁵ Stenosis is considered severe if the DSCA is < 75 mm² and moderate when it measures < 100 mm².⁶ More recently a grading system based on the morphology of the dural sac has been described and found to have prognostic value, with grades A and B less likely to need surgery and grades C

and D more likely to fail conservative treatment.⁷ The grading is summarised as follows: grade A: there is clearly cerebrospinal fluid (CSF) visible within the dural sac, but its distribution is heterogeneous. Grade A is subdivided into subgroups A1 to A4: A1, the rootlets lie dorsally and occupy less than half of the dural sac area; A2, the rootlets lie dorsally, in contact with the dura but in a horseshoe configuration; A3, the rootlets lie dorsally and occupy more than half of the dural sac area; and A4, the rootlets lie centrally and occupy the majority of the dural sac area. Grade B: the rootlets occupy the whole of the dural sac, but they can still be individualised. Some CSF is still present giving a grainy appearance to the sac. Grade C: no rootlets can be recognised, the dural sac demonstrating a homogeneous gray signal with no CSF signal visible. There is epidural fat present posteriorly. Grade D: in addition to no rootlets being recognisable there is no epidural fat posteriorly (Fig. 1). This morphological grading entirely disregards the absolute value of the DSCA, as it mainly considers the CSF/rootlet

■ C. Schizas, MD, PD, FRCS,
Orthopaedic Spine Surgeon
■ G. Kulik, PhD, Spine Research
Co-ordinator
Centre Hospitalier Universitaire
Vaudois, Hôpital Orthopédique,
CHUV-University of Lausanne,
Av P. Decker 4, Lausanne 1011,
Switzerland.

Correspondence should be sent
to Mr C. Schizas; e-mail:
cschizas@hotmail.com

©2012 British Editorial Society
of Bone and Joint Surgery
doi:10.1302/0301-620X.94B1.
27420 \$2.00

J Bone Joint Surg Br
2012;94-B:98–101.

Received 20 April 2011;
Accepted after revision 10
August 2011

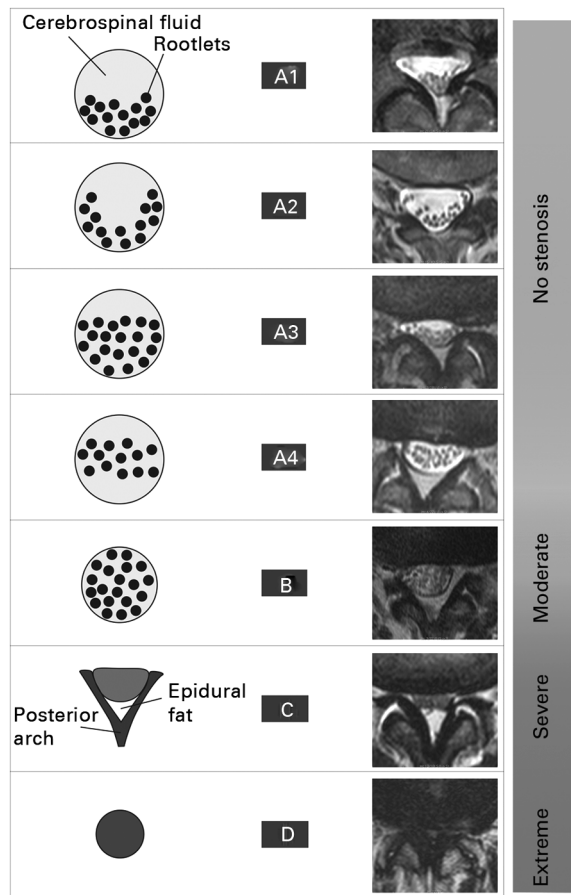


Fig. 1

Diagrams showing the morphological classification of severity of lumbar spinal stenosis of Schizas et al⁷ (reproduced with permission from Lippincott Williams & Wilkins).

ratio.⁷ The contrasting appearance of nerve roots and CSF on axial T₂-weighted MRI scans makes such visual appraisal straightforward. This dimension-free grading is independent of the vertebral level and image acquisition techniques, such as slice orientation.⁸ Even though the morphological grading was shown to have a certain relationship with DSCA, a significant overlap of grades for a given surface measurement has been reported. Particularly on axial T₂-weighted MRI, images with DSCA > 100 mm² can be observed without any visible CSF corresponding to myelographic blocs (grades C and D). Conversely, axial images with DSCA < 75 mm² and ample room for nerve tissue surrounded by CSF can also be observed (grades A and B). Finally, no relationship between morphological grading and surgical results has been reported, but this has been attributed to the use of non-disease-specific outcome tools.

We performed a study to see whether those who treat patients with lumbar spinal stenosis based their decision as far as imaging is concerned on DSCA measurements.

Table I. The characteristics of the ten MRI cases presented in the survey

Stenosis morphology grade	Dural sac cross-sectional area (mm ²)	Vertebral level
A1	161	L2/3
A2	226	L3/4
A3	118	L2/3
A4	161	L2/3
B	40	L4/5
B	70	L3/4
B	141	L2/3
C	95	L4/5
C	126	L4/5
D	14	L4/5

Material and Methods

Axial T₂-weighted MRI scans of the lumbar spines of ten different patients with either low back pain or lumbar spinal stenosis were selected so as to include all four grades and a wide range of DSCA values. Their mean DSCA was 115 mm² (14 to 126); the morphological grades ranged from A1 to D (four As, three Bs, two Cs and one D; Fig. 1).

One image from each patient was used to illustrate 20 hypothetical clinical scenarios. These ten images were presented initially in an increasing morphological grading severity score (first ten case scenarios). The images were reshuffled and shown again in a different order, this time giving the DSCA value in mm² (ten remaining case scenarios). For all images the actual level was disclosed (four at L2/3 level, two at L3/4 and four at L4/5). We deliberately introduced one grade B image with a DSCA < 100 mm² and a grade C image with a DSCA > 100 mm² in order to further verify the concept that physicians base their decision on morphology (Table I).

The question was worded as follows: ‘We are conducting a study on the variability of surgical indications in lumbar spinal stenosis based on the appreciation of severity of narrowing of the spinal canal. You will be shown 20 T₂ axial images. The question we would like to answer is the following: Assuming the MR images correspond to 20 patients who have severe neurological claudication symptoms and who are fit for surgery, would you consider decompressing their lumbar spine given the degree of stenosis shown on those 20 images?’

Background questions were also asked, as follows: number of years of post-fellowship practice, specialty (orthopaedics or neurosurgery), country of practice, and prior knowledge of the morphological classification. A space was also left for free text. This survey was organised on a webpage and an electronic link was sent to one international and two national spine societies (Eurospine, British Association of Spinal Surgeons and the Swiss Spine Society, with a total membership of 651 physicians).

As the main outcome measure we used the number of cases for whom responders offered decompressive surgery

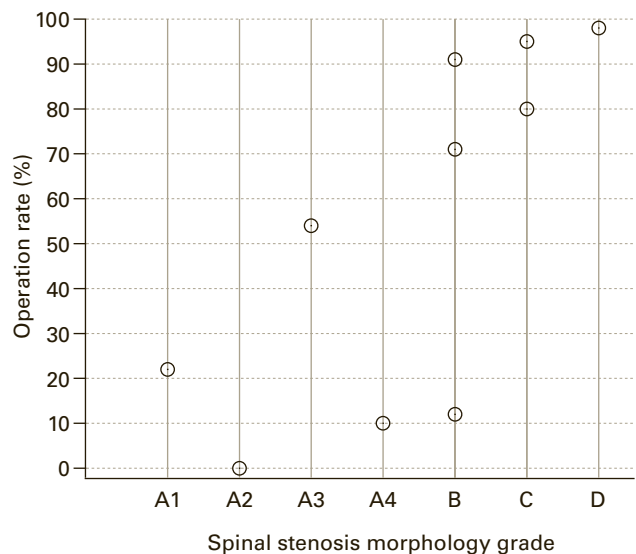


Fig. 2

The distribution of operative rates for each grade following disclosure of dural sac cross-sectional area.

for a given morphological grade. Results were further analysed according to the following parameters: number of years in practice (< ten or > ten), specialty (orthopaedic surgery or neurosurgery), prior knowledge of the classification, opinion change on disclosure of DSCA, and density of physicians in the country of practice. Information on physician density was obtained from the European Statistics Office official webpage (<http://epp.eurostat.ec.europa.eu>), which grades states into five different density categories. We set the cut-off value between high and low density at 305 physicians per 100 000 inhabitants.

Statistical analysis was performed using Fisher's exact test with a p -value < 0.05 to signify statistical significance.

Results

A total of 142 responses were received, 137 of which were valid and five were incomplete. From those 137, a total of 100 originated from orthopaedic surgeons, 30 from neurosurgeons, and seven from physicians from other specialties involved in treating spinal conditions (rheumatology, rehabilitation and radiology). Responses were obtained from 25 different countries. A total of 2740 clinical scenarios were therefore available for analysis (1370 with morphological grade information and the same 1370 with DSCA information). Only forty responders (29%) were aware of the morphological grading of stenosis.

In all 41 responders (30%) added some free text and 23 of these emphasised the need to base surgical decisions on complete patient assessment.

A total of 117 of 545 (21%) grade A images, 236 of 412 (57%) grade B images, 238 of 272 (88%) of grade C images and 133 of 136 (98%) of all grade D images were

considered suitable for decompressive surgery. More cases with C and D grades were considered for decompression than those with A or B grades. This difference was statistically significant ($p < 0.001$). A distribution of operative rates for each grade can be seen in Figure 2.

In all, 487 of 549 (89%) cases with a DSCA < 100 mm² and 241 of 816 (29%) with a DSCA > 100 mm² were considered for surgery. This difference was also statistically significant ($p < 0.001$). Subsequent disclosure of the DSCA under each image did not result in a difference in numbers of levels to be decompressed ($p = 1.0$).

Grade C cases were considered more often for surgery by neurosurgeons than by orthopaedic surgeons ($p = 0.0048$). In other grades no difference between specialties was noted.

The number of years in practice, physician density and prior knowledge of the morphological grading did not influence the decision to operate, whether it was based on the grading or the DSCA.

Discussion

The main finding of our study was that subsequent disclosure of the DSCA under each image did not result in a change in opinion of the requirement for decompression. This reflects the fact that surgeons overall rely more on the morphological appearance of the dural sac than on surface measurements in deciding which patients are suitable for surgery.

Despite the fact that physicians opted for surgery in most cases with B, C or D stenosis or cases with DSCA < 100 mm², they were more likely to be influenced by the morphology of the dural sac rather than its surface measurements, as transpired from the responses given to the cases of B grade < 100 mm² and C grade > 100 mm². On the other hand, most surgeons would operate on grade B cases. This appears to conflict with previous research showing that surgery on patients with grade B stenosis was not necessary during a 3.1 year follow-up period.⁷ So far there have been no other studies validating this finding.

Basing the decision to operate on morphology is not new. Prior to the advent of CT or MRI, surgeons relied mainly on the morphology of the dural sac as shown on radiculography, with complete block regarded as a surgical indication. The morphological grading reflects this, as grade C or D stenosis appears to correspond to complete myelographic block.⁷ It has been confirmed that myelographic blocks can be seen at the L4/5 level of symptomatic patients with DSCA of 70 mm² to 138 mm².⁹

Even though guidelines exist for several interventional procedures in patients with symptomatic spinal pathology¹⁰ and spinal stenosis,¹ to our knowledge no clear guidelines exist for surgery relative to the radiological severity of spinal stenosis. This survey might not reflect actual decision-making, which could be influenced by several other factors (clinical, financial and access to health resources). It can nevertheless be regarded as an unbiased report of current beliefs on the surgical indications for decompression in patients with spinal stenosis.

Although the response rate in our survey appears to be low, it compares with other surveys: 26% on an e-mail survey to paediatricians¹¹ and 15% among surgeons.¹² Low response rates are one of the limitations of surveys; others are measurement, sampling error and coverage.¹³ It has been suggested that a 50% response rate at least is necessary, for conclusions to be drawn.¹⁴ It is unfortunately a fact that response rates are declining with the passage of years.¹⁵ Ways to improve survey responses have been suggested, for example combining several methods, such as internet and surface mailing.^{16,17}

This survey was performed using images to illustrate different scenarios, and physicians had therefore no access to patient history or physical examination, and this was reflected by the free text remarks of 23 responders. The case description was nevertheless clear in that it described fictional symptoms of neurological claudication severe enough to warrant surgery in otherwise fit patients. Additionally, spinal stenosis surgery is based primarily on the patient's history with concordant imaging studies, as neurological examination at rest is often normal. Obviously other pathologies such as osteoarthritis of the hip and peripheral vascular disease must be excluded by examination. In this survey we constructed our clinical scenarios in such a way as to leave respondents with sufficient clinical information to decide on the appropriateness of surgery, in the presence of the radiological severity of stenosis shown on axial MRI scans.

Several authors have reported a significant variation in surgical practices in relation to geographical location.^{18,19} This variability has been described also for lumbar laminectomy and discectomy, but no data on isolated lumbar decompressive surgery are available.²⁰ Although our survey did not address the question of total number of procedures per country, we found no significant variation in opinion as far as the threshold for spinal decompression is concerned. Appropriateness criteria for spinal surgery have been previously studied²¹ and have been found to be related to surgical outcomes.²² To our knowledge, no other study has looked into the variation of surgical indications for lumbar decompressive surgery relative to the radiological severity of stenosis. Even though most surgeons had not come across the morphological classification their decision to proceed to surgery was based on the morphology of the dural sac and not on DSCA measures. An attempt to mislead the respondents with images of morphological stenosis but with DSCA > 100 mm² failed. This further supports the view that surgeons base their judgment on morphology.

In conclusion, we found that spinal surgeons across large geographical regions of Europe base surgical decisions on

the morphology of the dural sac rather than on DSCA. Grading the severity of radiological stenosis based on morphology is probably more relevant than measuring DSCA.

No benefits in any form have been received or will be received from a commercial party related directly or indirectly to the subject of this article.

References

1. **Watters WC 3rd, Baisden J, Gilbert TJ, et al.** Degenerative lumbar spinal stenosis: an evidence-based clinical guideline for the diagnosis and treatment of degenerative lumbar spinal stenosis. *Spine J* 2008;8:305–310.
2. **Amundsen T, Weber H, Nordal HJ, et al.** Lumbar spinal stenosis: conservative or surgical management?: a prospective 10-year study. *Spine* 2000;25:1424–1435.
3. **Weinstein JN, Tosteson TD, Lurie JD, et al.** Surgical versus nonsurgical therapy for lumbar spinal stenosis. *N Engl J Med* 2008;358:794–810.
4. **Malmivaara A, Slätis P, Heliövaara M, et al.** Surgical or nonoperative treatment for lumbar spinal stenosis?: a randomized controlled trial. *Spine* 2007;32:1–8.
5. **Hamanishi C, Matukura N, Fujita M, Tomihara M, Tanaka S.** Cross-sectional area of the stenotic lumbar dural tube measured from the transverse views of magnetic resonance imaging. *J Spinal Disord* 1994;7:388–393.
6. **Schönström N, Lindahl S, Willén J, Hansson T.** Dynamic changes in the dimensions of the lumbar spinal canal: an experimental study in vitro. *J Orthop Res* 1989;7:115–121.
7. **Schizas C, Theumann N, Burn A, et al.** Qualitative grading of severity of lumbar spinal stenosis based on the morphology of the dural sac on magnetic resonance images. *Spine* 2010;35:1919–1924.
8. **Henderson L, Kulik G, Richarme D, Theumann N, Schizas C.** Is spinal stenosis assessment dependent on slice orientation?: a magnetic resonance imaging study. *Eur Spine J* 2011;Epub.
9. **Penning L, Wilmsink JT.** Posture-dependent bilateral compression of L4 or L5 nerve roots in facet hypertrophy: a dynamic CT-myelographic study. *Spine* 1987;12:488–500.
10. **Manchikanti L, Boswell MV, Singh V, et al.** Comprehensive evidence-based guidelines for interventional techniques in the management of chronic spinal pain. *Pain Physician* 2009;12:699–802.
11. **McMahon SR, Iwamoto M, Massoudi MS, et al.** Comparison of e-mail, fax, and postal surveys of pediatricians. *Pediatrics* 2003;111:299–303.
12. **Leece P, Bhandari M, Sprague S, et al.** Correction and republication: internet versus mailed questionnaires: a controlled comparison (2). *J Med Internet Res* 2004;6:85–93.
13. **Groves RM.** *Survey errors and survey costs.* New York: Wiley Interscience, 1989:81–184,239–356.
14. **Babbie E.** *The practice of social research.* Ninth ed. Belmont: Wadsworth Publishing Company, 2001:252.
15. **Dillman DA, Eltinge JL, Groves RM, Little R.** Survey nonresponse in design, data collection, and analysis. In: Dillman DA, Eltinge JL, Groves RM, Little R, eds. *Survey nonresponse.* New York: John Wiley & Sons, 2002:3–26.
16. **Sprague S, Quigley L, Bhandari M.** Survey design in orthopaedic surgery: getting surgeons to respond. *J Bone Joint Surg [Am]* 2009;91-A:27–34.
17. **Kroth PJ, McPherson L, Leverence R, et al.** Combining web-based and mail surveys improves response rates: a PBRN Study From PRIME Net. *Ann Fam Med* 2009;7:245–248.
18. **Deyo RA, Mirza SK.** Trends and variations in the use of spine surgery. *Clin Orthop* 2006;443:139–146.
19. **Angevine PD, Arons RR, McCormick PC.** National and regional rates and variation of cervical discectomy with and without anterior fusion: 1990-1999. *Spine* 2003;28:931–939.
20. **Weinstein JN, Lurie JD, Olson PR, Bronner KK, Fisher ES.** United States' trends and regional variations in lumbar spine surgery: 1992-2003. *Spine* 2006;31:2707–2714.
21. **Porchet F, Vader JP, Larequi-Lauber T, et al.** The assessment of appropriate indications for laminectomy. *J Bone Joint Surg [Br]* 1999;81-B:234–239.
22. **Danon-Hersch N, Samartzis D, Wietlisbach V, Porchet F, Vader JP.** Appropriateness criteria for surgery improve clinical outcomes in patients with low back pain and/or sciatica. *Spine* 2010;Epub.